

# Treating smile disease

By Ashish Parmar BDS

In this article, Ashish Parmar explores the concept of 'smile design' as taught by the Rosenthal Group. Using a case report, it is explained how the important steps in smile design are applied to create a beautiful smile using porcelain veneers

## WHAT IS SMILE DISEASE?

The lower third of the face is very important when looking at facial beauty. If someone has nice lips which smoothly open up like curtains when they smile to reveal well aligned, correctly shaped, whiter teeth, then that person is likely to be more attractive. For a number of reasons (e.g. someone is nervous, or dentally uneducated), people have unattractive smiles. Figures 1 & 2 show two examples of smile disease of varying severity.

## THE PRINCIPLES OF SMILE DESIGN

There are seven principles in smile analysis and tooth preparation techniques:

- Size of the central incisors and golden proportion rules
- Position of the midline
- Archform
- Axial inclination
- Gingival height symmetry (including 'zenith' position)

- The buccal corridor and 'gradation'
- Contact areas and embrasure spaces.

## THE CENTRAL INCISORS

The central incisors are the dominant actors in the stage of someone's smile. They must be symmetrical with proper incisal edge position and should not have a discrepancy or variance of more than 0.2mm in any direction. It is also important to establish a 75-80% width/length ratio (Figure 3).

If the midline is considered a mirror plane, it is important to have symmetrical central incisors, but not necessarily a symmetrical smile. With subtle contralateral variation, a natural smile is created if there is balance.

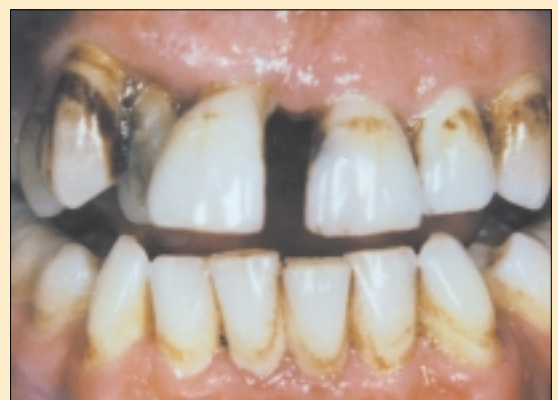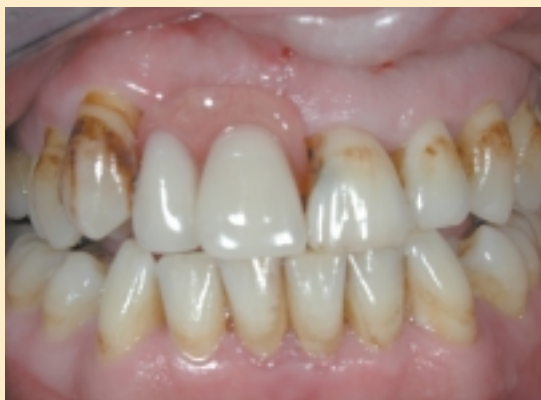Using the principle of golden proportion, it is possible to use a pre-operative photograph (a two dimensional image) to assess if the ratio between the central incisor : lateral incisor : canine is 1.6 : 1 : 0.6 (Figure 4).

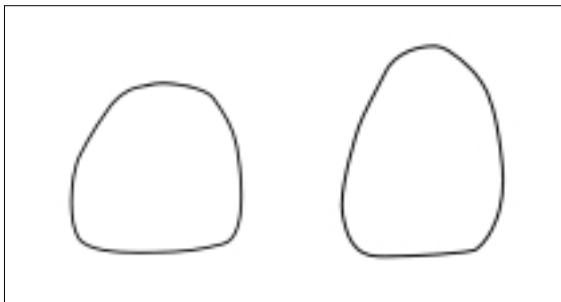
## THE MIDLINE

The upper midline should be vertical and not canted or inclined. It does not necessarily have to be in the middle of the face. The use of a facebow in multiple veneer cases can help

**Ashish Parmar BDS**  
practises aesthetic and  
implant dentistry at the  
**Perfect Smile Studios**

Figures 1 & 2: Smile disease of varying severity





**Figure 3:** A 'short/square tooth' compared with one of correct shape and size

the technician set up the working model correctly on a semi-adjustable articulator.

If the centre line needs to be shifted, then more aggressive tooth reduction is necessary to open up contacts. Important concepts include:

- Removing more tooth substance distally to create space
- Utilising more units of teeth for space distribution
- Use of a soft tissue laser for papilla recontouring.

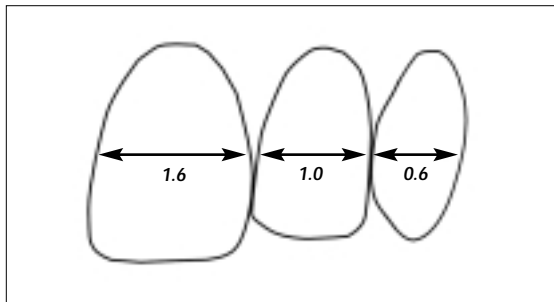
### ARCHFORM

When planning for veneer treatment, it is very useful to assess the archform on a pre-operative study cast. Certain teeth may be too labial, and certain teeth lingual to an imaginary line of the ideal curved archform required. With a marker, areas that need to be reduced first are marked on the model ('archform reduction') (Figure 5 to 7).

### AXIAL ALIGNMENT

An example of a situation where the alignment needs to be improved is a mesially inclined upper lateral incisor (e.g. class 2 division 2 occlusion). More tooth reduction will be necessary mesially to improve the alignment of the prepared tooth.

In this initial smile design preparation, it is important to keep in mind that the preparation margins are not being established and the focus is solely on achieving the correct



**Figure 4:** The principles of the 'golden proportion'

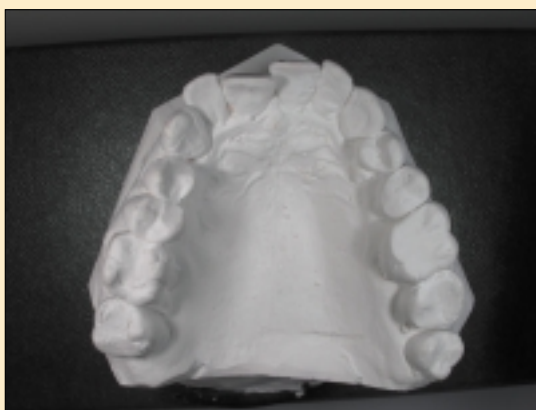midline position, to have better archform (where necessary) and to achieve the proper axial inclinations of all the prepared teeth.

### GINGIVAL HEIGHTS

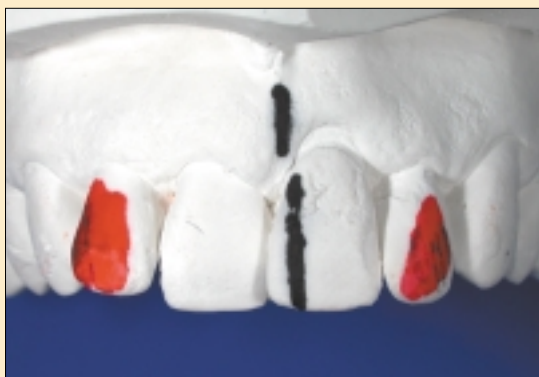It is recommended to have:

- Equal gingival height of the central incisor and the canine
- The gingival height of the lateral incisor 0.5 - 1.0mm shorter than the central incisor and canine
- The zenith (the highest point of the gingiva) slightly distal of the midline for the central incisor and the canine, and in the midline for the lateral incisor (Figures 8a & 8b).

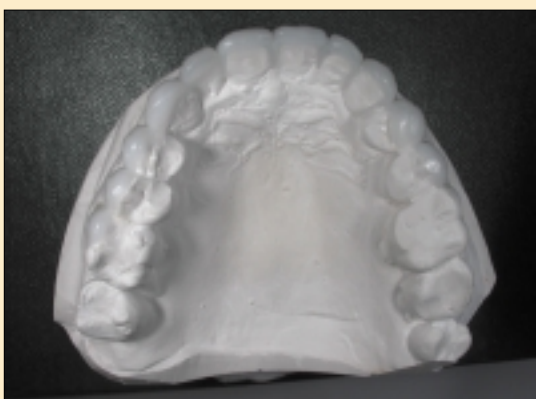
**Figure 5:** Pre-operative occlusal view



**Figure 6:** Markings on model (e.g. centre line shift/'midline slice' and areas of bulk reduction)



**Figure 7:** Wax-ups to improve archform



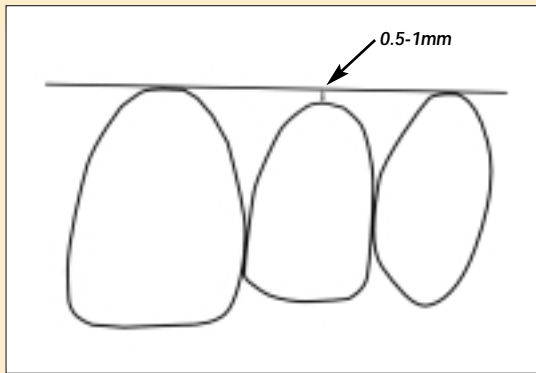


Figure 8a: Recommended gingival heights - equal for the central incisor and the canine, but 0.5-1mm shorter for the lateral incisor

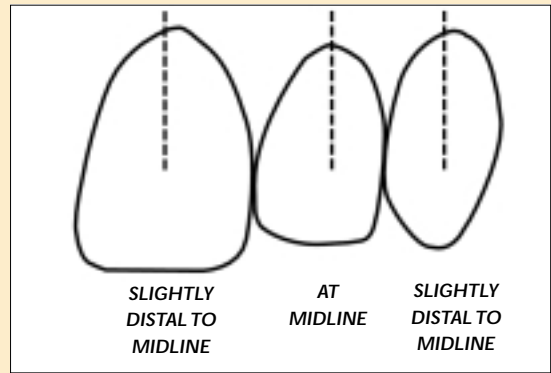


Figure 8b: Preferred positions for the zenith (the highest point of the gingiva) - slightly distal of the midline for the central incisor and the canine, and in the midline for the lateral incisor

In addition, Dr Rosenthal personally prefers to have the upper lateral incisor zenith slightly distal to midline.

To do high quality, efficient and effective gum recontouring a soft tissue diode laser (e.g. Twilite) is invaluable. Using such a laser, only seven to ten cell layers are removed at a time, there is no bleeding and minimal or no post-operative discomfort. This allows immediate impression taking (Figure 9).

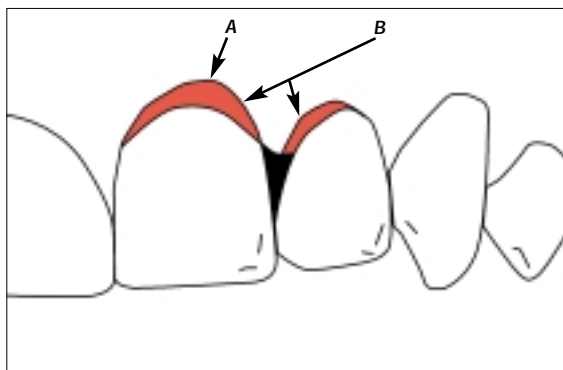
**LASERING OR CROWN LENGTHENING (OSSEOUS RECONTOURING)?**

In the pre-operative assessment, if there are labial pockets of 3-4mm or more, then the use of a soft tissue laser is appropriate. If there is no pocketing and a 'gummy smile' needs to be corrected, then osseous recontouring and 'crown lengthening' will be required first.

**THE BUCCAL CORRIDOR**

Correcting the 'lateral negative space' or improving the 'buccal corridor' is important in creating an aesthetically beautiful smile. This may involve veneering the first, and often the second premolars depending on the person's smile. It is often

Figure 9: A=laser surgery repositioning of gingival zenith distal to midline of central incisor. B=laser surgery gingival 'troughing' to allow porcelain veneer contours to close the 'black triangle' area



necessary to do some laser contouring cervically and bring the buccal cusps tips outward. This has a beneficial effect of supporting the lips better for a more youthful smile (Figures 10 & 11).

**GRADATION**

There should be a smooth gradation in size from the anterior or incisor region to the posterior premolars and molar region.

Figure 10: Cross-section of a premolar

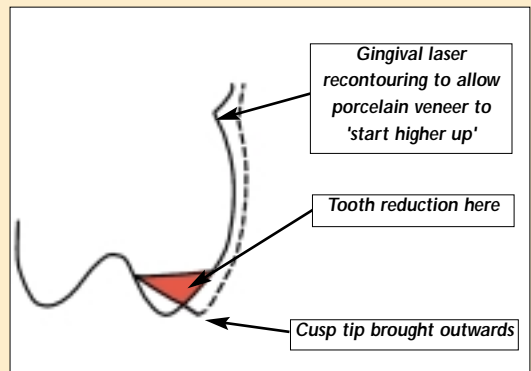
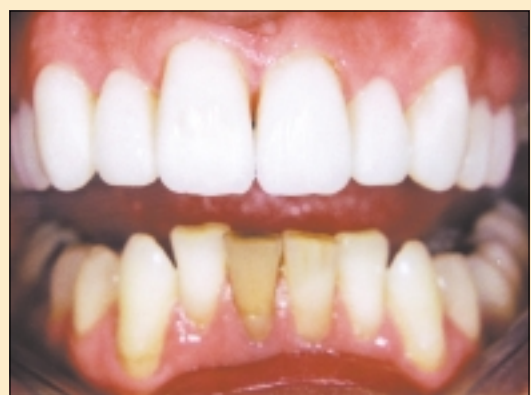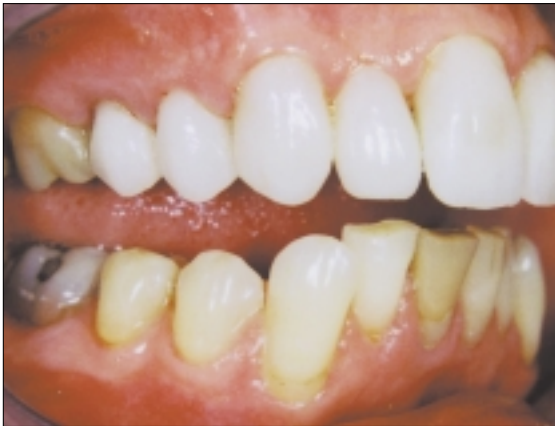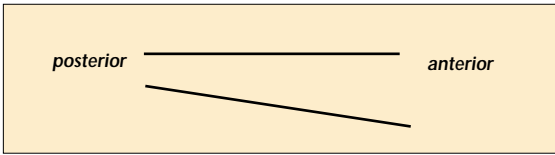


Figure 11: Veneers on upper premolars for a 'fuller' buccal corridor





**Figures 11 & 12: A correct curve of spee ensures a harmonious and natural appearance from a side view**

A correct curve of spee ensures a harmonious and natural appearance from a side view (Figures 11 & 12).

### CONTACT AREAS

The central incisors should have a contact area in the lower one third. The lateral incisor has a contact area in the middle one third. For the canine, ideally it should be higher still. But, people may not like this as the canine ends up looking more pointed. Therefore the contact point is often brought lower (Figure 4).

### CASE HISTORY

This patient is a pleasant lady who was nervous of receiving dental treatment. After some routine periodontal care and restorations, she expressed an interest in improving her smile. Her main concerns were to have whiter teeth and to improve the unfavourable positions of the upper lateral incisors. After careful discussion, the patient decided not to have crown lengthening. The lower teeth were whitened using 15% carbamide peroxide and a bleaching tray using home whitening techniques. The front ten upper teeth were treated with all ceramic crowns and porcelain veneers.

### PRE-OPERATIVE ASSESSMENT/PLANNING

This included:

- Complete dental examination and 'smile analysis'
- Radiographs (full mouth periapicals and a dental panoramic tomograph)
- Articulated study casts\*
- Digital photographs (using a Nikon Coolpix 990 Camera)
- Polaroid pictures (using a Macro 5 Polaroid Camera)

- Trial preparations by the laboratory technician on a duplicate model (using smile design principles)
- Diagnostic wax-ups
- A siltec putty index or an ellman splint.

\*It is recommended to use 'putty and wash' impressions rather than alginates so that multiple models can be easily produced by the technician.

### THE PREPARATION DAY

Key features are:

- Get the patient relaxed (soothing music helps)
- Good local anaesthesia
- Take a facebow reading and a 'stump shade' (Polaroid picture with the nearest shade from a Vita 3D-Master shade guide next to a prepared anterior tooth)
- Use Luxatemp (colours available are BL, A1, A2 and A3.5) for temporaries (allow up to one hour for making superb temporary restorations!) (Figure 13).

Tips include:

- Create tapered necks
- Build out the middle thirds
- 'Roll in' the incisal thirds
- Open embrasures (fine burs/orange sofflex discs)
- 'Tucked in' lateral incisors
- Change mesial/distal line angles to 'widen' or 'narrow' a tooth
- Establish the correct final lengths of the central incisors
- Use flowable composite (e.g. Ecuflow) to build out areas, fill in airblows or deficiencies
- Use Luxaglaze at the end for a glossy appearance.

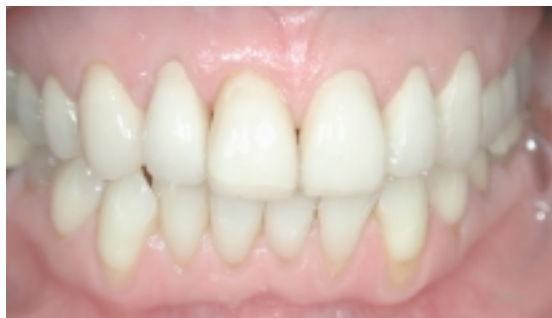### THE FIRST REVIEW APPOINTMENT (ONE TO THREE DAYS AFTER)

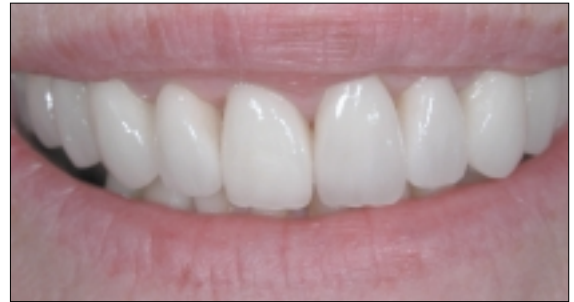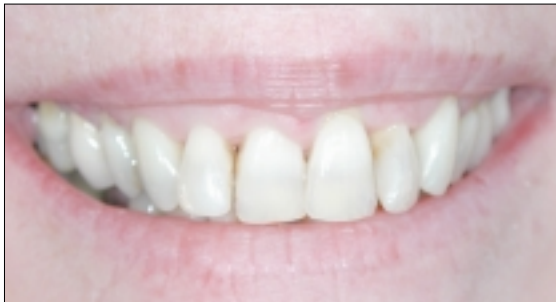An opportunity to get the patient's views on:

- The shape, size and position of teeth
- Colour of temporaries
- Phonetics.

Further recontouring of the temporaries can be done to

**Figure 13: Temporary restorations at the end of the preparation visit**





Figures 14 & 15: Before and after

get an ideal appearance. At this point, a Polaroid photograph and an alginate of the accepted temporaries is taken for the technician.

### THE SHADE SELECTION APPOINTMENT

One of the most important tasks of the dental ceramist is at the shade selection appointment. This is the art of matching teeth to people as all patients have different requirements. An example would be a 21-year-old female who wishes to have the perfect smile as seen on the cover of *Cosmopolitan*, the illusion of perfect white teeth framed between parted lips contrasting white against a vermillion background enhanced by lipstick. In this scenario an ideal mix of porcelains would be:

- Centrals - Vita OM3 / 1M1
- Laterals - Vita 1M1
- Canines - Vita 1M1 / B1.

High levels of translucency built into the incisal area to enhance mammelon structures within. However, not everyone wants a 'Hollywood' smile and for a more natural appearance there are several other factors to be considered:

- Patient's age
- Gingival colouration
- Texture and Lustre
- Male/female
- Shape of restorations (male angular/female curved).

### LIGHTING CONDITIONS

A good tip here is never take the shade with the patient laying in the dental chair, always with the patient standing at eye level. Utilise natural and Waldman Colour-I-Dent shade selection light to compliment each other.

### THE FITTING APPOINTMENT

Key points are:

- Local anaesthesia if necessary (you want a relaxed patient who's not jumpy)
- Use of rubber dam (two holes punched about one inch apart; joint together by a scissor cut; clamps on molars bilaterally)

- Use of Consepsis scrub to clean teeth
- Use of a good bonding system e.g. Variolink II
- Seating in one go if possible (use of serrated saw blade #9816 by Brasseler, floss and brushes before cement sets hard interproximally and near margins)
- Recontouring porcelain veneers as necessary (for aesthetic improvement and occlusion checking)
- Polishing with Shofu Porcelain Laminate Polishing Kit and then Luminescence Diamond Polishing Paste
- The celebration! Let your patient appreciate his or her new smile. Have your team members around.

### THE SECOND REVIEW APPOINTMENT

See the patient a couple of days later for:

- Patient feedback and ensuring all is well.
- Rechecking of occlusion.
- Post-operative photographs (Figures 14 & 15).

### ACKNOWLEDGEMENT

I would like to thank Dr Larry Rosenthal, Dr Peter Rinaldi, Dr Jay Lerner and all the other instructors for hosting a truly wonderful six-day course in January 2002. Through their inspiration and training, it is now possible to aim for the highest levels of aesthetic dentistry possible for our patients in the UK.

I would also like to thank Rob Storrar for his exquisite ceramic work. Beauty is created when art and science are blended well. ■

### MATERIALS & EQUIPMENT

- Twillite (Biolase, [www.biolase.com](http://www.biolase.com))
- Siltec putty index & Variolink II (Ivoclar Vivadent, 0116 2654055)
- Splint (Ellman International, [www.ellman.com](http://www.ellman.com))
- Diamond Polishing Paste (Shofu, 01472 399609)
- Luxatemp & Luxaglaze (Minerva, 029 20490504)
- Colour-I-Dent (Waldmann, [www.waldmann.com](http://www.waldmann.com))
- Consepsis scrub (Optident, 01965 605050)
- Ecuflow (DMG, [www.dmg-hamburg.de](http://www.dmg-hamburg.de))